



Diagnostic importance of P16 in the differential diagnosis of well-differentiated liposarcoma and lipomas

Pegah Hedayat¹, Maryam Derakhshan¹, Laya Golshani², Arash Hedayat³

¹Department of Pathology, Isfahan University of Medical Sciences, Isfahan, Iran

²Pathology Medicine Department, Isfahan University of Medical Sciences, Isfahan, Iran

³Internal Medicine Department, Isfahan University of Medical Sciences, Isfahan, Iran

*Correspondence to

Laya Golshani,

Email:

layagolshani@gmail.com

Received 29 Jun. 2023

Accepted 17 Sep. 2023

ePublished 29 Jan. 2024

Keywords: Lipoma, Well-differentiated liposarcoma, Immunohistochemistry

Abstract

Introduction: Because of pathological overlaps, distinguishing well-differentiated liposarcoma (WDL) from lipoma is difficult.

Objectives: The purpose of this study was to evaluate P16 as a differentiating marker for WDL and lipomas

Materials and Methods: This cross-sectional study was performed on 38 pathology samples of lipoma and WDL in the department of pathology of Al-Zahra hospital, affiliated with Isfahan university of medical sciences, from 2011 to 2018. The studied samples were examined by immunohistochemistry (IHC) to determine the presence of P16.

Results: Evaluation of IHC data showed that all of the lipoma samples (100%) had a score of 0 for IHC staining. In comparison, 84.2% of liposarcoma samples had a score of 3, and this difference was statistically significant ($P < 0.001$). Evaluating the sensitivity and specificity of P16 gene expression showed that this marker has 84% sensitivity and 100% specificity for diagnosing liposarcoma (95% CI: 0.6042-0.9661).

Conclusion: The use of p16 to differentiate WDL from lipoma has a sensitivity of 84% and a specificity of 100%, which could be very helpful in pathological practice.

Citation: Hedayat P, Derakhshan M, Golshani L, Hedayat A. Diagnostic importance of P16 in the differential diagnosis of well-differentiated liposarcoma and lipomas. *Immunopathol Persa*. 2024;x(x):e40558. DOI:10.34172/ipp.2023.40558.

Introduction

lipoma is the most prevalent soft tissue tumor that arises from the mesoderm. A fibrous membrane separates the lipoma's periphery and is filled with mature adipocytes and cells of mesoderm origin. There are numerous variations based on the other constituents. The neck, back, and limb subcutaneous tissue is the most common location for developing lipomas (1,2).

The most common kinds of soft tissue sarcoma are liposarcoma (15%) and leiomyosarcoma (5%-10%) (3). They are frequently the subject of clinical studies. Liposarcoma typically develops in the limbs, trunk, or retroperitoneum and rarely in the gastrointestinal system. Liposarcoma can present with a wide range of histologic forms, including well-differentiated, myxoid, round cell, pleomorphic, and dedifferentiated (4, 5). Approximately 40%-45% of occurrences are classified as well-differentiated liposarcomas (WDLs). Similar to mature-type adipose tissue, WDL also features nuclear atypia and expansion within adipose tissue and fibrous stroma, as well as fibrous septation (6-8).

Key point

P16 gene expression has 84% sensitivity and 100% specificity for differentiating well-differentiated liposarcoma and lipoma.

Atypical lipomatous tumors (ALTs) image characteristics are very similar to WDL. It is known that WDL and ALTs are the same things because they both describe lesions that look the same and have the same karyotype. Site-specific differences in behavior only have to do with how easy it is to remove the tumor with surgery (9).

WDL should be closely monitored due to its tendency to recur and dedifferentiate, and the capacity to metastasize. However, lipomas can be conservatively monitored unless patients have symptoms as a result of the mass's presence. Pathologists may find it difficult to distinguish between WDL and lipoma due to pathological overlaps. Immunohistochemistry (IHC) has allowed pathologists to better categorize tumors (10-12). As a way to differentiate between cases of



this problem, we looked at P16 gene expression.

The P16 (encoded by cyclin-dependent kinase inhibitor 2A; CDKN2A) has been proposed as a diagnostic marker for WDL due to its ability to inhibit cell cycle progression by binding to the CDK4/cyclin D1 complex. Moreover, p16 IHC is widely available in laboratories. When fluorescence in situ hybridization (13) is not readily available or when the cost or time of the test is a key factor, p16 IHC has been offered as a suitable alternative for identifying WDL and lipomas and it is a sensitive marker for WDL(14-16).

Objectives

The present study aims to evaluate P16 as a differentiating marker for WDL versus lipomas.

Materials and Methods

This cross-sectional study was conducted on 38 pathology samples of lipoma and WDL from 2011 to 2018 in the department of pathology of Al-Zahra hospital affiliated with Isfahan University of Medical Sciences. The clinical/pathological variables, such as age, gender, tumor type, grade of malignancy, and degree of differentiation were obtained. The inclusion criteria were a paraffin block of samples in the archive of the Al-Zahra hospital pathology unit, appropriate quality of the block for sampling, and documented grading of the tumor in the pathology report. Doubtful slides or slides that need IHC investigation to confirm were excluded.

Histopathology

One expert pathologist examined the histopathology slides. Each paraffin block initially yielded two slides. The first slide was stained with hematoxylin and eosin (H&E) to determine the kind of tumor. The second slide, designed for IHC, was stained using a labeled antibody following the kit's manufacturer's instructions. The samples were then examined by light microscopy to detect the presence of P16 expression. The following is a report on P16 expression in the samples; Initially, the intensity of staining was assessed using 10-Ounce lens and assigned negative, poor, or strong staining. The second step was to analyze nuclear staining with a 40-Ounce lens, and they were scored from 0 to 3 points this time. Score 0 indicated no staining, score 1 stated less than 10% and focal nucleus staining, score 2 showed 11%-50% and multifocal nucleus staining, and score three indicated more than 50% and widespread nucleus staining. Cytoplasmic and membrane staining were also considered negative.

Statistical analysis

An independent *t* test and chi-square test were conducted during data evaluation by Statistical Package for Social Sciences (SPSS) version 24. Quantitative data were reported as mean± standard deviation and qualitative data as frequency distribution (percentage). The results were evaluated as a 95% confidence interval (CI) and

significance was set at $P < 0.05$.

Results

We collected 38 samples from 23 males (60.5%) and 15 females (39.5%) with a mean age of 45.08 ± 16.61 years. We examined all 19 WDL and 19 lipoma samples with the 10-Ounce lens before scoring them with the 40-Ounce lens. The analysis of IHC data revealed that all lipoma samples (100%) had an IHC staining score of 0 while 84.2% of WDL samples had a score of 3, and these differences were statistically significant ($P < 0.001$; Table 1).

There are no statistically significant differences between the IHC scores with genders and the mean age (Table 2).

Evaluating the sensitivity and specificity of P16 gene expression showed that this marker has 84% sensitivity and 100% specificity for the diagnosis of WDL (95% CI: 0.6042-0.9661) (Table 3; Figure 1).

Discussion

Numerous articles have discussed the frequent instances of disagreement among pathologists, and statistics show about 42% of initial sarcoma diagnoses were incorrect (17-19). Since pathologists have difficulty differentiating WDL from lipoma(10), we looked at p16 as a facilitating maker. Our results demonstrate that p16 is an excellent diagnostic tool for WDL, with a sensitivity of 84% and a specificity of 100%.

Our results are consistent with the study by Kammerer-Jacquet et al, which detected that p16 had a sensitivity of 89.5% and a specificity of 68.2% in the differential diagnosis of ALTs/WDL and benign adipocytic tumors (20). Previously Thway et al in a review study on the use of various markers for identifying WDL from lipoma, found p16, MDM2, and CDK4 are useful markers with discrimination power (8).

In another study at New Jersey medical school, 50 cases of lipomatous neoplasms with cytogenetic results were gathered. P16 was found in 25/30 (83.3%) of the ALT/WDL but not in any of the deep-seated lipomas (0/18) ($P < 0.0001$). Based on these findings, p16 shows promise in distinguishing ALT/WDL from subcutaneous lipomas (21). Another study by Ng et al presents a case of massive retroperitoneal adipocytic mass in a 27-year-

Table 1. Comparison of two tumor types based on IHC grades

	Type		Total	P value
	Liposarcoma	Lipoma		
IHC	0	0 (0.0)	19 (100.0)	< 0.001
	1	2 (10.5)	0 (0.0)	
	2	1 (5.3)	0 (0.0)	
	3	16 (84.2)	0 (0.0)	
	Total	19 (50)	19 (50)	

IHC; Immunohistochemistry.
Data is presented by No. (%).

Table 2. Evaluation of IHC score based on age and gender

		IHC				Total	P value
		0	1	2	3		
Age (y), mean±SD		38±14	50±24	41	53±17	45.08±16.61	0.146
Gender, No. (%)	Male	10 (43.5)	1 (4.3)	1 (4.3)	11 (47.8)	23 (60.5)	0.791
	Female	9 (60.0)	1 (6.7)	0 (0.0)	5 (33.3)	15 (39.5)	

Table 3. Evaluation of IHC score based on sensitivity and specificity

IHC	Sensitivity (%)	95% CI		Specificity (%)	95% CI	
		Lower band	Upper band		Lower band	Upper band
0	100	0.798	1.000	100	0.798	1.000
1	89.5	0.671	0.981	100	0.798	1.000
2	84.2	0.614	0.951	100	0.798	1.000
3	00.00	0.000	0.202	100	0.798	1.000

IHC, Immunohistochemistry.

old man that was clinically and radiologically consistent with WDL. This mass was a differentiated adipocytic tumor with significant fibrous septa and fat necrosis, more resembling a retroperitoneal lipoma. In sites of fat necrosis, IHC revealed diffuse, high nuclear expression of p16. Nevertheless, CDK4 was negative, and FISH revealed no evidence of MDM2 amplification in the lesion. Thus, they highlight the importance of adding p16 as part of a panel with CDK4 +/- MDM2 in distinguishing between WDL and lipoma (11).

Another study by Sagar et al demonstrated that 100% of malignant and intermediate adipocytic tumors had positive p16 immunohistochemical expression significantly (22). In addition, Knösel et al showed that the expression of p16 was observed in 88.9% of liposarcoma (23). Likewise, the diagnostic utility of p16 for challenging cases of dedifferentiated liposarcoma was proven in a prior

study, with sensitivities and specificities of 100% and 60%, respectively (24).

In line with our research, Thway et al conducted a study in 2012 exploring the diagnostic usefulness of p16 in distinguishing between WDL and lipoma. It was reported that the sensitivity and specificity of p16 gene expression for differentiating WDL and lipoma were 93% and 92% respectively (13). Another study by Gonzalez et al suggested employing p16 for the differential diagnosis of ALT/WDLs in laboratories where efficiency and economy are top priorities (16).

Previous studies tried to differentiate WDL/ALTs from lipomas based on the intratumoral septal structures, magnetic resonance imaging (MRI) findings, and size. It is well known that adipocytic tumors, whether benign or malignant, can grow quite large without causing any symptoms, and MRI is not readily available in all healthcare facilities (25-29).

Conclusion

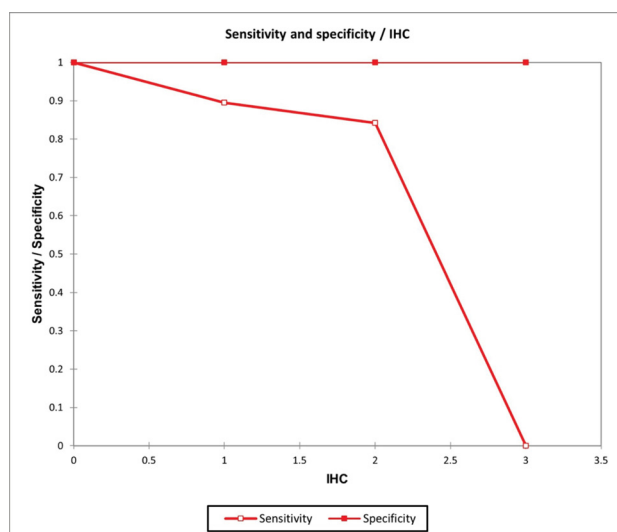
The use of p16 to distinguish WDL from lipoma has 84% sensitivity and 100% specificity, which could be very helpful in pathological practice. We believe that paying attention to tumor depth, radiologic abnormalities, diagnostic second opinions, and pathological markers, particularly p16, at the same time could reduce diagnostic errors (21,30).

Limitations of the study

Our study had some limitations. Evaluating more slides and other markers such as MDM2 and CDK4 is not possible due to economic limitations. Hence more investigations are required to discover whether p16 is a differentiating factor on a large scale.

Acknowledgements

We would like to thank the research committee of our university

**Figure 1.** ROC curve of P16 gene expression for the diagnosis of well-differentiated liposarcoma.

and Dr. Aryan Rafiee Zadeh for his efforts during this research.

Authors' contribution

Conceptualization: Pegah Hedayat.

Data curation: Arash Hedayat.

Formal analysis: Laya Golshani.

Methodology: Maryam Derakhshan.

Project Administration: Laya Golshani.

Resources: Maryam Derakhshan.

Supervision: Pegah Hedayat.

Writing—original draft: Laya Golshani.

Writing—review and editing: Arash Hedayat.

Conflicts of interest

The authors declare that they have no competing interests.

Ethical issues

The study adhered to the principles of the Declaration of Helsinki and received approval from the Ethics Committee of Isfahan University of Medical Sciences (Ethical code# IR.MUI.MED.REC.1398.609). Informed consent was obtained from participants upon hospital admission. This research was conducted as the residency thesis of Laya Golshani at the Department of Pathology, Isfahan University of Medical Science.

Funding/Support

This study was partially funded by a grant from the Isfahan University of Medical Sciences (Grant #398860).

References

- Bancroft LW, Kransdorf MJ, Peterson JJ, O'Connor ML. Benign fatty tumors: classification, clinical course, imaging appearance, and treatment. *Skeletal Radiol.* 2006;35:719-33. doi: 10.1007/s00256-006-0189-y.
- Rydholm A, Berg NO. Size, site and clinical incidence of lipoma. Factors in the differential diagnosis of lipoma and sarcoma. *Acta Orthop Scand.* 1983;54:929-34. doi: 10.3109/17453678308992936.
- Puri A, Gulia A. Management of extremity soft tissue sarcomas. *Indian J Orthop.* 2011;45:301-6. doi: 10.4103/0019-5413.82332.
- Kobayashi E, Naito Y, Asano N, Maejima A, Endo M, Takahashi S, et al. Interim results of a real-world observational study of eribulin in soft tissue sarcoma including rare subtypes. *Jpn J Clin Oncol.* 2019;49:938-946. doi: 10.1093/jjco/hyz096.
- Miao RC, Wan Y, Zhang XG, Zhang X, Deng Y, Liu C. Devascularization of the superior mesenteric vein without reconstruction during surgery for retroperitoneal liposarcoma: A case report and review of literature. *World J Gastroenterol.* 2018;24:2406-2412. doi: 10.3748/wjg.v24.i22.2406.
- Coindre JM, Mariani O, Chibon F, Mairal A, De Saint Aubain Somerhausen N, Favre-Guillevin E, et al. Most malignant fibrous histiocytomas developed in the retroperitoneum are dedifferentiated liposarcomas: a review of 25 cases initially diagnosed as malignant fibrous histiocytoma. *Mod Pathol.* 2003;16:256-62. doi: 10.1097/01.MP.0000056983.78547.77.
- Huang HY, Brennan MF, Singer S, Antonescu CR. Distant metastasis in retroperitoneal dedifferentiated liposarcoma is rare and rapidly fatal: a clinicopathological study with emphasis on the low-grade myxofibrosarcoma-like pattern as an early sign of dedifferentiation. *Mod Pathol.* 2005;18:976-84. doi: 10.1038/modpathol.3800381.
- Thway K. Well-differentiated liposarcoma and dedifferentiated liposarcoma: An updated review. *Semin Diagn Pathol.* 2019;36:112-121. doi: 10.1053/j.semdp.2019.02.006.
- Jo VY, Fletcher CD. WHO classification of soft tissue tumours: an update based on the 2013 (4th) edition. *Pathology.* 2014;46:95-104. doi: 10.1097/PAT.000000000000050.
- Laurino L, Furlanetto A, Orvieto E, Dei Tos AP. Well-differentiated liposarcoma (atypical lipomatous tumors). *Semin Diagn Pathol.* 2001;18:258-62.
- Ng W, Messiou C, Smith M, Thway K. p16 Expression in Fat Necrosis: A Potential Diagnostic Pitfall in the Evaluation of Differentiated Adipocytic Neoplasms. *Int J Surg Pathol.* 2015;23:544-8. doi: 10.1177/1066896915595465.
- Doyle AJ, Pang AK, Miller MV, French JG. Magnetic resonance imaging of lipoma and atypical lipomatous tumour/well-differentiated liposarcoma: observer performance using T1-weighted and fluid-sensitive MRI. *J Med Imaging Radiat Oncol.* 2008;52:44-8. doi: 10.1111/j.1440-1673.2007.01910.x.
- Thway K, Flora R, Shah C, Olmos D, Fisher C. Diagnostic utility of p16, CDK4, and MDM2 as an immunohistochemical panel in distinguishing well-differentiated and dedifferentiated liposarcomas from other adipocytic tumors. *Am J Surg Pathol.* 2012;36:462-9. doi: 10.1097/PAS.0b013e3182417330.
- Serrano M. The tumor suppressor protein p16INK4a. *Exp Cell Res.* 1997;237:7-13. doi: 10.1006/excr.1997.3824.
- Singer S, Socci ND, Ambrosini G, Sambol E, Decarolis P, Wu Y, et al. Gene expression profiling of liposarcoma identifies distinct biological types/subtypes and potential therapeutic targets in well-differentiated and dedifferentiated liposarcoma. *Cancer Res.* 2007;67:6626-36. doi: 10.1158/0008-5472.CAN-07-0584.
- Gonzalez RS, McClain CM, Chamberlain BK, Coffin CM, Cates JM. Cyclin-dependent kinase inhibitor 2A (p16) distinguishes well-differentiated liposarcoma from lipoma. *Histopathology.* 2013;62:1109-11. doi: 10.1111/his.12112.
- Ray-Coquard I, Montesco MC, Coindre JM, Dei Tos AP, Lurkin A, Ranchère-Vince D, et al. Sarcoma: concordance between initial diagnosis and centralized expert review in a population-based study within three European regions. *Ann Oncol.* 2012;23:2442-2449. doi: 10.1093/annonc/mdr610.
- Katenkamp D. Cellular heterogeneity. Explanation for changing of tumor phenotype and biologic behavior in soft tissue sarcomas. *Pathol Res Pract.* 1988;183:698-705. doi: 10.1016/S0344-0338(88)80055-4.
- Coindre JM, Nguyen BB, Goussot JF, de Mascarel I, Maree D, de Mascarel A, et al. Modifications histologiques après chimiothérapie des sarcomes des tissus mous de l'adulte [Histological changes after chemotherapy of soft tissue sarcomas in the adult]. *Ann Pathol.* 1985;5:95-9.
- Kammerer-Jacquet SF, Thierry S, Cabillic F, Lannes M, Burtin F, Henno S, et al. Differential diagnosis of atypical lipomatous tumor/well-differentiated liposarcoma and dedifferentiated liposarcoma: utility of p16 in combination with MDM2 and CDK4 immunohistochemistry. *Hum Pathol.* 2017;59:34-40. doi: 10.1016/j.humpath.2016.08.009.
- He M, Aisner S, Benevenia J, Patterson F, Aviv H, Hameed M. p16 immunohistochemistry as an alternative marker to distinguish atypical lipomatous tumor from deep-seated lipoma. *Appl Immunohistochem Mol Morphol.* 2009;17:51-6. doi: 10.1097/PAI.0b013e3181719223.
- Sagar M, Yadav R, Deval P, Kumar M, Maurya MK, Qayoom S. Immunohistochemical Expression of p16 and CDK4 in Soft Tissue Tumors. *Cureus.* 2023;15:e35713. doi: 10.7759/cureus.35713.
- Knösel T, Altendorf-Hofmann A, Lindner L, Issels R, Hermeking H, Schuebbe G, et al. Loss of p16(INK4a) is associated with reduced patient survival in soft tissue tumours, and indicates a senescence barrier. *J Clin Pathol.* 2014;67:592-8. doi: 10.1136/jclinpath-2013-202106.
- Kobayashi A, Sakuma T, Fujimoto M, Jimbo N, Hirose T.

- Diagnostic Utility and Limitations of Immunohistochemistry of p16, CDK4, and MDM2 and Automated Dual-color In Situ Hybridization of MDM2 for the Diagnosis of Challenging Cases of Dedifferentiated Liposarcoma. *Appl Immunohistochem Mol Morphol*. 2019;27:758-763. doi: 10.1097/PAI.0000000000000677.
25. Nagano S, Yokouchi M, Setoguchi T, Ishidou Y, Sasaki H, Shimada H, et al. Differentiation of lipoma and atypical lipomatous tumor by a scoring system: implication of increased vascularity on pathogenesis of liposarcoma. *BMC Musculoskelet Disord*. 2015;16:36. doi: 10.1186/s12891-015-0491-8.
 26. Yuri T, Miyaso T, Kitade H, Takasu K, Shikata N, Takada H, et al. Well-differentiated liposarcoma, an atypical lipomatous tumor, of the mesentery: a case report and review of the literature. *Case Rep Oncol*. 2011;4:178-85. doi: 10.1159/000327266.
 27. Gaskin CM, Helms CA. Lipomas, lipoma variants, and well-differentiated liposarcomas (atypical lipomas): results of MRI evaluations of 126 consecutive fatty masses. *AJR Am J Roentgenol*. 2004;182:733-9. doi: 10.2214/ajr.182.3.1820733.
 28. Lucas DR, Nascimento AG, Sanjay BK, Rock MG. Well-differentiated liposarcoma. The Mayo Clinic experience with 58 cases. *Am J Clin Pathol*. 1994;102:677-83. doi: 10.1093/ajcp/102.5.677.
 29. Sommerville SM, Patton JT, Luscombe JC, Mangham DC, Grimer RJ. Clinical outcomes of deep atypical lipomas (well-differentiated lipoma-like liposarcomas) of the extremities. *ANZ J Surg*. 2005;75:803-6. doi: 10.1111/j.1445-2197.2005.03519.x.
 30. Sbaraglia M, Bellan E, Dei Tos AP. The 2020 WHO Classification of Soft Tissue Tumours: news and perspectives. *Pathologica*. 2021;113:70-84. doi: 10.32074/1591-951X-213.