



Treatment outcomes of total laryngectomy followed by localized radiotherapy in patients with locally advanced laryngeal squamous cell carcinoma; a retrospective study

Ahmed Nabil Elsamanody¹, Ahmed Seleim¹, Mohammed Abdelfattah Eltawy¹, Ahmed Seddik Abdelglil Mohammed¹, Sherif Azzam^{2*}, Eslam Mohamed M. Ibrahim², Mohamed Abdelfattah³, Mohamed Abd El-Rahman Alkenawy³, Ahmed Seif Elnasr Sedeek³, Mahmoud Mohamed Aboumandour Fouda³, Sameh Zayed^{4,5}, Ashraf Y. Hegab^{4,6}, Hashem Bark A. Abood⁷, Tamer A.A. Samih⁸, Hasan A. Soltan⁹

¹Department of Otorhinolaryngology, Faculty of Medicine, Al-Azhar University, Cairo, Egypt

²Department of Clinical Oncology and Nuclear Medicine, Faculty of Medicine, Al-Azhar University, Cairo, Egypt

³Department of Radiodiagnosis and Intervention Radiology, Faculty of Medicine, Al-Azhar University, Cairo, Egypt

⁴Prince Mishari bin Saud Hospital in Baljurashi, Al-Baha Health Cluster, Ministry of Health, Al-Baha, Saudi Arabia

⁵Department of Otorhinolaryngology, Ministry of Health, Cairo, Egypt

⁶Department of Internal Medicine, Ministry of Health, Cairo, Egypt

⁷Department of Surgery, King Fahad Hospital, Al-Baha Health Cluster, Ministry of Health, Al-Baha, Saudi Arabia

⁸Department of Radiology, Faculty of Medicine, Benha University, Benha, Egypt

⁹Department of Radiology, Faculty of Medicine, Aswan University, Aswan, Egypt

*Correspondence to

Sherif Azzam, Email: sherif.azzam@azhar.edu.eg

Received 31 May 2025

Revised: 15 Aug. 2025

Accepted 23 Aug. 2025

ePublished 30 Aug. 2025

Keywords: Larynx, Laryngeal carcinoma, Radiotherapy, Total laryngectomy



Citation:

Elsamanody AN, Seleim A, Eltawy MA, Mohammed ASA, Azzam Sh, Ibrahim EMM, Abdelfattah M, Alkenawy MAE, Sedeek ASE, Fouda MMA, Zayed S, Hegab AY, Abood HBA, Samih TAA, HA. Treatment outcomes of total laryngectomy followed by localized radiotherapy in patients with locally advanced laryngeal squamous cell carcinoma; a retrospective study. Immunopathol Persa. 2026;12(1):e43936. DOI:10.34172/ipp.2025.43936.

Abstract

Introduction: Locally advanced laryngeal squamous cell carcinoma often requires aggressive treatment. Total laryngectomy followed by radiotherapy remains a standard approach for achieving local control and improving survival when organ preservation is not feasible.

Objectives: To evaluate the morbidity and mortality outcomes of patients with locally advanced laryngeal cancer (LC) managed with total laryngectomy followed by postoperative radiotherapy (TLPR) at a tertiary hospital in Egypt.

Patients and Methods: This retrospective study included patients with a pathological diagnosis of T3 or T4 locally advanced LC treated with TLPR between 2017 and 2021, with a follow-up period of 33 months. Clinical and demographic variables, including age, gender, smoking status, tumor sub-site, TNM (tumor, node, metastasis) classification, clinical staging, pathological features, treatment modality, preoperative tracheostomy, postoperative fistula, and associated comorbidities, were collected and analyzed for their relationship to prognosis.

Results: A total of 84 patients were included in the study, with a mean age of 52.93 years (range: 26–82 years) and a male-to-female ratio of 68% to 32%. Among the patients, 45.2% achieved complete response, 28.5% had partial response, 16.8% experienced stable disease, and 9.5% showed disease progression. Frequent relapse occurred in 22 patients. The mean overall survival was 57.29 ± 62.14 weeks (range: 8–242 weeks), while the mean progression-free survival was 26.81 ± 40.92 weeks (range: 6–225 weeks).

Conclusion: Postoperative radiotherapy following total laryngectomy is an effective strategy for achieving better disease control and long-term survival in patients with locally advanced laryngeal squamous cell carcinoma.

Introduction

The frequency of head and neck cancers has varied over the years, with laryngeal cancer (LC) accounting for approximately one-third of these cases. Laryngeal cancer is among the most common malignant lesions occurring in the head and neck region (1).

Advanced LC generally refers to stages III–IV according to the Union for International Cancer Control (UICC)/American Joint Committee on Cancer (AJCC) staging

system (2). These cancers are classified using the TNM (tumor/node/metastasis) staging criteria. T3 LC is characterized by vocal cord fixation, paraglottic space invasion, pre-epiglottic space invasion, post-cricoid extension, or minor thyroid cartilage erosion (2,3).

Accurate staging of LC requires meticulous clinical and radiological evaluation (2). One of the challenges in staging is the potential subjectivity in defining criteria, particularly

Key point

- Total laryngectomy followed by radiotherapy achieved a complete response in 45.2% of patients with advanced laryngeal cancer.
- The mean overall survival was 57.29 weeks, and the mean progression-free survival was 26.81 weeks.
- Disease relapse occurred in 22 patients, with 9.5% showing disease progression.
- TLPR remains an effective treatment strategy for local control and long-term survival in advanced laryngeal squamous cell carcinoma cases.

for T3 classification (3,4). Vocal cord fixation is a key feature of T3 classification and is widely recognized as a significant predictor of poor outcomes with non-surgical treatment. In recent years, survival rates for LC patients have declined from 57.1% to 51.9%, in contrast to increasing survival rates for other tumors (5,6).

For T4 LC, total laryngectomy combined with radiotherapy is typically recommended (7). In contrast, early-stage tumors (T1 or T2) can often be managed with either conservative surgery or radiotherapy. For T2 or T3 tumors requiring total laryngectomy, organ preservation approaches, such as radiotherapy following induction chemotherapy or chemoradiotherapy with cisplatin, are preferred (8,9).

Objectives

This study aims to evaluate the morbidity and mortality outcomes of patients with locally advanced LC (stage IV) managed through total laryngectomy and postoperative radiotherapy (TLPR).

Patients and Methods**Study design and participants**

This retrospective study reviewed data from 84 consecutive patients with stage III or IV locally advanced LC treated between January 2017 and December 2021 at a tertiary referral center in Egypt. All diagnoses were histologically confirmed as squamous cell carcinoma. Staging was conducted using computed tomography (CT) and magnetic resonance imaging (MRI), and all patients underwent total laryngectomy with neck dissection followed by either radiotherapy or chemoradiotherapy. The AJCC 8th Edition staging system was used to classify disease stage, with particular focus on stage IVa supraglottic carcinoma (2).

Inclusion and exclusion criteria**Inclusion criteria**

- Histologically confirmed squamous cell carcinoma of the larynx
- Stage III or IV disease (T3 or T4, N0–N3, M0)
- Underwent total laryngectomy followed by postoperative radiotherapy or chemoradiotherapy
- Complete treatment records and at least 36 months of follow-up

Exclusion criteria

- Presence of distant metastases at diagnosis
- Non-squamous histology
- Incomplete treatment
- Insufficient follow-up data

Data collection

Clinical and demographic data were extracted from medical records. Variables included:

- Age, gender, smoking history
- Tumor subsite and TNM classification
- Clinical and pathological staging
- Treatment modality (radiotherapy or chemoradiotherapy)
- Preoperative tracheostomy, postoperative fistula
- Associated comorbidities

Staging and assessment of recurrence were confirmed through imaging, including CT, MRI, and positron emission tomography–computed tomography (PET-CT), as well as flexible or direct laryngoscopy, chest X-ray, and abdominal ultrasound (Figures 1 and 2). Histopathological confirmation was conducted for any suspicious recurrence or metastasis.

Outcomes

The primary outcomes were the comparison of overall survival and progression-free survival between stage III and IV (10). Secondary outcomes included assessment of the clinical response to treatment, specifically evaluating the rates of complete response, partial response, stable disease, and progressive disease, based on standardized imaging and clinical criteria (10,11).

Statistical analysis

Data were recorded in an Excel spreadsheet and analyzed using statistical software packages Statistical Analysis System (SAS) 9.2 (SAS Institute, Cary, NC, USA) and SPSS 15.0 (SPSS Inc., Chicago, IL, USA). Descriptive statistics were presented as means with standard deviations (SD) and ranges (min–max), while categorical data were expressed as frequencies and percentages. Meanwhile, chi-square test was conducted to evaluate associations between categorical variables, and the independent T-test was employed to compare means between groups for continuous variables. Survival distributions were estimated using Kaplan–Meier curves, and comparisons between survival curves were performed using the log-rank test. A *P* value of <0.05 was considered statistically significant.

Results

A total of 84 patients were included in this retrospective study, all treated at our institution by the same physician team, with external consultations conducted remotely when indicated. The mean age was 52.9 years (range: 26–82 years), with a predominance of male patients (Table 1). Table 2 shows that 28% of patients in stage III, had glottic cancer followed by supraglottic 37.5% and subglottic

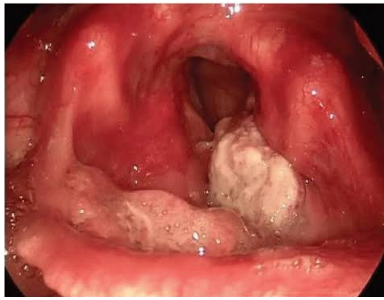

Figure 1. Endoscopic picture of left advanced supraglottic cancer demonstrating a bulky, irregular, and exophytic mass arising from the left supraglottic region, involving the epiglottis and extending toward the aryepiglottic fold. The lesion exhibits mucosal ulceration and obscures the view of the ipsilateral vocal fold. The surrounding mucosa appears erythematous and edematous, indicative of local inflammatory changes

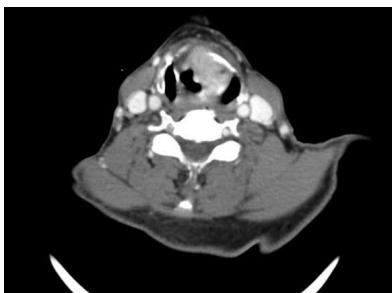


Figure 2. Axial contrast-enhanced CT scan of the neck showing an advanced left laryngeal carcinoma. The image reveals a heterogeneously enhancing soft tissue mass centered in the left hemilarynx, with clear evidence of invasion into the paraglottic space and transgression of the thyroid cartilage. The lesion causes partial obliteration of the airway lumen and extends across the midline, suggesting aggressive local spread

cancers (34.5.2%) without a significant deference in cases of stage IV.

In our study, most patients showed favorable treatment responses, with a higher proportion achieving complete or partial responses, while a minority had stable or progressive disease. Relapse occurred in a subset of patients. Overall survival and progression-free survival were notably longer in patients with stage III disease compared to those with stage IV. This difference was statistically significant and is further illustrated in [Figures 3–5](#) and [Table 3](#).

The most prevalent histological grade of the studied cases was the poorly differentiated carcinoma, followed by moderately differentiated carcinoma ([Figure 6](#)).

Discussion

Although survival rates for early-stage LC are high, survival remains relatively low for advanced LC. Early-stage LC (stages I and II) has a survival rate of 73%–92%, compared to 35%–51% for advanced-stage LC (stages III and IV) (12,13). Our findings showed a 3-year survival rate of 68.1% for advanced LC, which is slightly higher than previously reported in the literature.

Table 1. Distribution of the studied cases according to demographic data

Variables	Stage III (32 cases)	Stage IV (52 cases)	P value
Sex			
Male	17 (53%)	33 (63.5%)	0.349*
Female	15 (47%)	19 (36.5%)	
Age (y)			
Min–Max	26.0–82.0	38.0–75.0	0.153**
Mean \pm SD	52.93 \pm 15.92	49.72 \pm 21.45	
Median (IQR)	54.0 (46.0–65.0)	59.0 (52.0–65.0)	
Smoking			
No	19 (59%)	41 (78.8%)	0.055*
Yes	13 (41%)	11 (21.2%)	

*Chi-square test, ** Independent T-test.

Table 2. Distribution of the studied cases according to diagnostic data (n = 84)

Diagnostic data	Stage III (32 cases)	Stage IV (52 cases)	P value
Site			
Supraglottic	12 (37.5%)	18 (34.6%)	0.703*
Glottic	9 (28.1)	10 (19.2%)	
Subglottic	11 (34.3%)	24 (46.2%)	
Lymph node			
Ipsilateral	12 (37.5%)	19 (36.5%)	0.986*
Bilateral	20 (62.5%)	33 (63.5%)	

*Chi-square test.

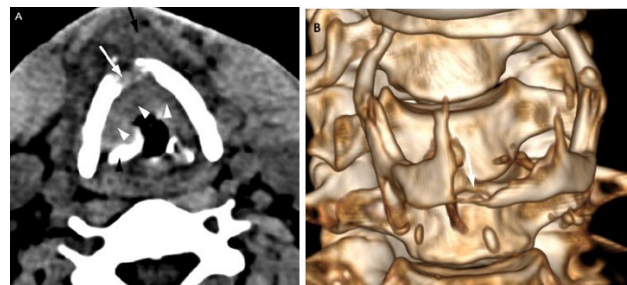


Figure 3. (A, B) CT and 3D reconstructed imaging of glottic carcinoma with cartilage and soft tissue invasion.

This discrepancy may be attributed to several factors, including the predominance of glottic cancer in our cohort, advancements in laryngeal surgery, efforts to ensure negative surgical margins, and a consistent postoperative follow-up protocol (14).

The effect of age on prognosis remains controversial. Ramroth et al identified age as a significant factor affecting outcomes in multivariable analysis (15). Other studies reported age as a prognostic factor only in univariable analysis but not as an independent determinant (16). Our study supports Ramroth and colleagues' findings, demonstrating that increased age independently predicts higher mortality risk.

Postoperative radiotherapy has been debated for its efficacy in advanced LC. Several studies have shown that postoperative radiotherapy does not significantly improve

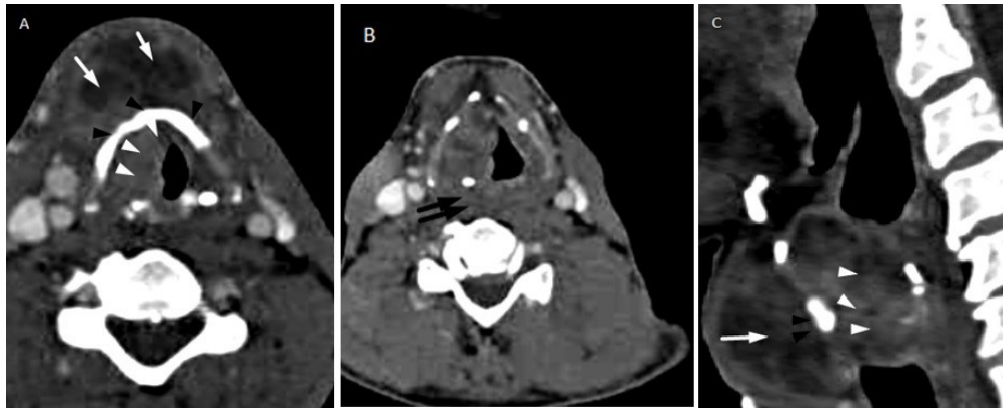


Figure 4. CT imaging features of advanced trans-glottic laryngeal carcinoma. (A) Axial CT image shows a heterogeneous, necrotic soft tissue mass (white arrowheads) involving the right aryepiglottic fold, true and false vocal cords, anterior commissure, and right paraglottic space. The lesion extends into the infraglottic space, causing obliteration of the airway column. (B) Focal sclerosis and erosion of the anterior portions of the thyroid cartilage and bilateral arytenoid cartilages are seen (black arrowhead), indicating cartilage infiltration. (C) The mass infiltrates the pre-glottic space and strap muscles, producing a focal contour bulge with intact overlying skin (white arrows). Posterior extension into the prevertebral muscles on the left side is noted, with loss of a clear cleavage plane (double black arrows).

outcomes in advanced LC patients (15,17). Similarly, our findings indicated that postoperative radiotherapy did not significantly enhance survival compared to surgery alone. However, it performed better than chemoradiotherapy alone in stage IVA-B LC. Recurrence rates were higher in the postoperative radiotherapy group, likely due to the advanced clinical stage and poor histological differentiation in this subset (18).

The clinical relevance of definitive radiotherapy has diminished due to evidence from “RTOG 91-11”, which showed worse local control, distant metastasis rates, and laryngeal preservation outcomes with postoperative radiotherapy alone compared to chemoradiotherapy (19). The current standard of care for advanced LC is definitive chemoradiotherapy or total laryngectomy followed by adjuvant Postoperative radiotherapy or chemoradiotherapy (20). Our study highlighted thyroid cartilage invasion as an independent factor negatively affecting overall survival and disease-free survival. Consequently, we support the limited role of nonsurgical organ preservation strategies (e.g., chemoradiotherapy) in cases with thyroid cartilage invasion (stage IVA), emphasizing the superiority of total

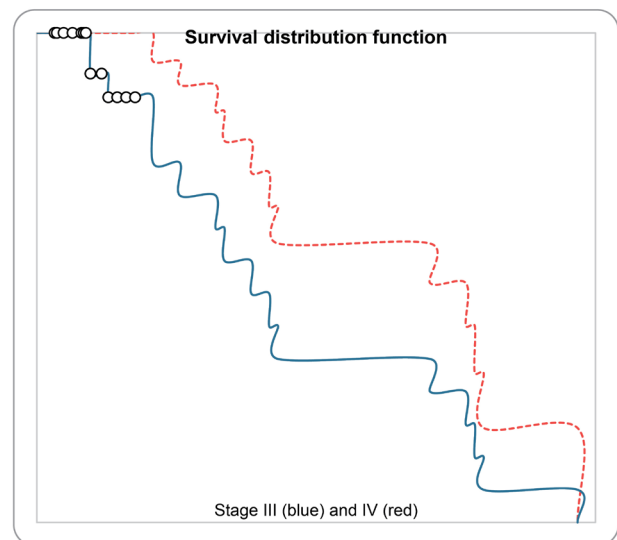


Figure 5. The Kaplan-Meier survival curve illustrating overall survival (OS) among the studied patient cohort. The curve shows a gradual decline in survival probability over time, reflecting the progressive nature of the disease. A steeper drop in the curve indicates periods of higher mortality. The survival distribution suggests that patients had variable outcomes, with a portion surviving significantly longer than others, highlighting heterogeneity in prognosis.

Table 3. Distribution of the studied cases according to treatment and prognosis

Characteristics	Stage III (32 cases)	Stage IV (52 cases)	Mean difference	P value
Response				
Complete	23 (71.8%)	31 (59.6%)		0.225*
Partial	9 (28.2%)	21 (40.4%)		
Overall survival (wk)				
Min.-Max.	8.0–122.0	6.0–95.0		
Mean ± SD.	57.29 ± 22.14	26.81 ± 31.92	30.5 weeks	0.025**
Median (IQR)	34.0 (25.0–80.0)	22.0 (18.0–42.0)		
Progression-free survival (wk)				
Min-Max	6.0–114.0	4.0–85.0		
Mean ± SD	31.0 ± 45.25	16.50 ± 35.25	14.5 weeks	0.016**
Median (IQR)	36.0 (28.0–75.0)	16.0 (12.0–63.5)		

*Chi-square test, ** Independent T-test.

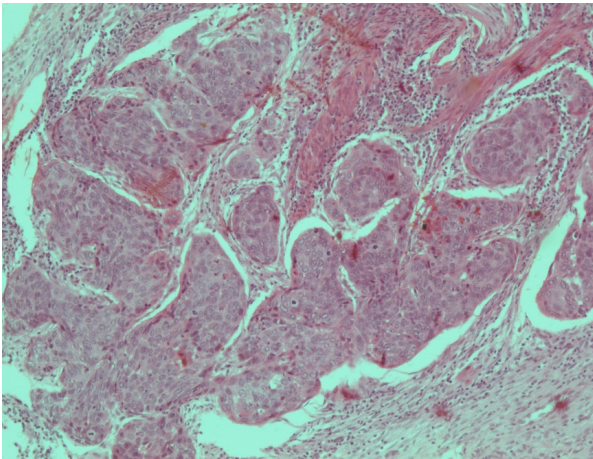


Figure 6. A histopathology picture of squamous cell carcinoma in larynx showing infiltrating multiple malignant cell nests formed of cells with enlarged hyperchromatic nuclei, prominent nucleoli and moderate pleomorphism (H&E, 100x).

laryngectomy followed by chemoradiotherapy (21,22). This study has several limitations. First, the sample size was relatively small, which may limit the statistical power and generalizability of the findings. Second, the retrospective design restricted data completeness, particularly for variables such as postoperative functional outcomes, detailed recurrence patterns, and specific causes of death. Third, occupational history was not recorded, which precluded assessment of the potential impact of workplace carcinogen exposure on LC incidence and prognosis.

Conclusion

Postoperative radiotherapy following total laryngectomy is a good helping tool to get better disease control and long-term survival of the locally advanced laryngeal squamous cell carcinoma. Multiple variables significantly associated with mortality in advanced LC include age, performance status, tumor site, clinical stage, pathological features, and treatment modality. These findings underscore the importance of tailored treatment approaches and rigorous follow-up for improved outcomes in advanced LC.

Limitations of the study

This study has several limitations. Its retrospective design may introduce selection bias and limit the accuracy of data collection. Being conducted at a single tertiary care centre also restricts the generalizability of the findings to broader populations. The absence of a control group receiving alternative treatment modalities, such as primary chemoradiotherapy or organ preservation strategies, limits direct comparisons of treatment efficacy. Additionally, data on functional outcomes, quality of life, and long-term treatment-related complications were not available, which may have provided a more comprehensive evaluation of patient outcomes.

Authors' contribution

Conceptualization: Ahmed Nabil Elsamanody, Ahmed Seleim,

Mohammed Abdulfattah Eltway, Ahmed Seddik Abdelglil Mohammed, Mohamed Abdelfattah, Sherif Azzam, Eslam Mohamed M. Ibrahim, Ahmed Seif Elnasr Sedeek, Mohamed Abd El-Rahman Alkenawy, Ashraf Y. Hegab, Mahmoud Mohamed Aboumandour Fouda, Sameh Zayed, Tamer A.A. Samih, Hasan Soltan.

Data curation: Ahmed Nabil Elsamanody, Ahmed Seleim, Mohammed Abdulfattah Eltway, Ahmed Seddik Abdelglil Mohammed, Mohamed Abdelfattah, Sherif Azzam, Eslam Mohamed M. Ibrahim, Ahmed Seif Elnasr Sedeek, Mohamed Abd El-Rahman Alkenawy, Hasan Soltan.

Formal analysis: Ahmed Seleim, Ahmed Nabil Elsamanody, Mohamed Abdelfattah, Sherif Azzam, Eslam Mohamed M. Ibrahim, Ahmed Seif Elnasr Sedeek.

Investigation: Ahmed Seleim, Ahmed Nabil Elsamanody, Mohamed Abdelfattah, Sherif Azzam, Eslam Mohamed M. Ibrahim, Ahmed Seif Elnasr Sedeek, Mohamed Abd El-Rahman Alkenawy, Ashraf Y. Hegab, Mahmoud Mohamed Aboumandour Fouda, Sameh Zayed, Hashim B. A. Abood, Tamer A.A. Samih, Hasan Soltan.

Methodology: Mohammed Abdulfattah Eltway, Ahmed Seddik Abdelglil Mohammed, Mohamed Abd El-Rahman Alkenawy, Ashraf Y. Hegab, Mahmoud Mohamed Aboumandour Fouda, Sameh Zayed, Tamer A.A. Samih, Hashim B. A. Abood, Hasan Soltan.

Project administration: Ahmed Nabil Elsamanody.

Resources: Ahmed Nabil Elsamanody, Sameh Zayed, Tamer A.A. Samih, Hasan Soltan.

Software: Sherif Azzam, Hashim B. A. Abood.

Supervision: Sherif Azzam.

Validation: Sherif Azzam.

Visualization: Ahmed Nabil Elsamanody, Tamer A.A. Samih, Hasan Soltan.

Writing—original draft: All authors.

Writing—review & editing: All authors.

Conflicts of interest

The authors declare that they have no competing interests.

Ethical Approval

The research conducted in this study adhered to the principles outlined in the Declaration of Helsinki and was approved by the Ethics Committee of Al-Azhar University, Faculty of Medicine (Ethical code #His-395-Research-00000148). Prior to any intervention, all participants provided written informed consent. The authors have fully complied with ethical issues, such as plagiarism, data fabrication, and double publication.

Funding

None.

References

1. Wong YF, Yusof MM, Wan Ishak WZ, Alip A, Phua VC. Treatment outcome for head and neck squamous cell carcinoma in a developing country: University Malaya Medical Centre, Malaysia from 2003–2010. *Asian Pac J Cancer Prev*. 2015;16:2903-8. doi:10.7314/apjcp.2015.16.7.2903.
2. Amin MB, Greene FL, Edge SB, Compton CC, Gershenwald JE, Brookland RK, et al. The Eighth Edition AJCC Cancer Staging Manual: Continuing to build a bridge from a population-based to a more "personalized" approach to cancer staging. *CA Cancer J Clin*. 2017;67:93-9. doi:10.3322/caac.21388.
3. Patel AM, Vedula S, Shaari AL, Choudhry HS, Filimonov A. Extranodal extension in laryngeal squamous cell carcinoma. *Laryngoscope Invest Otolaryngol*. 2024;9:e1232. doi:10.1002/lio2.1232.
4. Abo-Saif AI, Hasan A, Abdel-Maqsood RR, Ismail AN, Abdelazim HA, Elnelawy NE, et al. Assessment of immunohistochemical expression of cyclin D1 and E-cadherin

- in laryngeal squamous cell carcinoma. *J Med Chem Sci*. 2024;7:998-1010. doi:10.26655/JMCHEMSCI.2024.8.1.
5. McCoul ED, Har-El G. Meta-analysis of impaired vocal cord mobility as a prognostic factor in T2 glottic carcinoma. *Arch Otolaryngol Head Neck Surg*. 2009;135:479-86. doi:10.1001/archoto.2009.47.
6. Department of Veterans Affairs Laryngeal Cancer Study Group; Wolf GT, Fisher SG, Hong WK, Hillman R, Spaulding M, Laramore GE, et al. Induction chemotherapy plus radiation compared with surgery plus radiation in patients with advanced laryngeal cancer. *N Engl J Med*. 1991;324:1685-90. doi:10.1056/NEJM199106133242402.
7. Ono T, Tanaka N, Tanoue S, Miyata Y, Muraki K, Tsuji C, et al. Organ preservation following radiation therapy and concurrent intra-arterial low-dose cisplatin infusion for advanced T2 and T3 laryngeal cancer: Long-term clinical results from a pilot study. *Laryngoscope Investig Otolaryngol*. 2020;5:55-65. doi:10.1002/lto2.346.
8. Biau J, Pointreau Y, Blanchard P, Khampan C, Giraud P, Lapeyre M, et al. Radiotherapy for laryngeal cancers. *Cancer Radiother*. 2022;26:206-12. doi:10.1016/j.canrad.2021.09.004.
9. Siegel RL, Miller KD, Jemal A. Cancer statistics, 2016. *CA Cancer J Clin*. 2016;66:7-30. doi:10.3322/caac.21332.
10. Eisenhauer EA, Therasse P, Bogaerts J, Schwartz LH, Sargent D, Ford R, et al. New response evaluation criteria in solid tumours: Revised RECIST guideline (version 1.1). *Eur J Cancer*. 2009;45:228-47. doi:10.1016/j.ejca.2008.10.026.
11. Schwartz LH, Litière S, de Vries E, Ford R, Gwyther S, Mandrekar S, et al. RECIST 1.1—Update and clarification: From the RECIST committee. *Eur J Cancer*. 2016;62:132-7. doi:10.1016/j.ejca.2016.03.081.
12. Yilmaz T, Hoşal S, Ozyar E, Akyol F, Gürsel B. Post-operative radiotherapy in advanced laryngeal cancer: Effect on local and regional recurrence, distant metastases and second primaries. *J Laryngol Otol*. 2005;119:784-90. doi:10.1258/002221505774481183.
13. Spector JG, Sessions DG, Lenox J, Simpson J. Management of T3N1 glottic carcinoma: Therapeutic outcomes. *Laryngoscope*. 2006;116:106-10. doi:10.1097/01.mlg.0000184767.62682.3d.
14. Gourin CG, Conger BT, Sheils WC, Bilodeau PA, Coleman TA, Porubsky ES. The effect of treatment on survival in patients with advanced laryngeal carcinoma. *Laryngoscope*. 2009;119:1312-7. doi:10.1002/lary.20477.
15. Ramroth H, Schoeps A, Rudolph E, Dyckhoff G, Plinkert P, Lippert B, et al. Factors predicting survival after diagnosis of laryngeal cancer. *Oral Oncol*. 2011;47:1154-8. doi:10.1016/j.oraloncology.2011.08.003.
16. Yotakis J, Davris S, Kontozoglou T, Adamopoulos G. Evaluation of risk factors for stomal recurrence after total laryngectomy. *Clin Otolaryngol Allied Sci*. 1996;21:135-8. doi:10.1111/j.1365-2273.1996.tb01317.x.
17. Becker M, Zbären P, Casselman JW, Kohler R, Dulguerov P, Becker CD. Neoplastic invasion of laryngeal cartilage: Reassessment of criteria for diagnosis at MR imaging. *Radiology*. 2008;249:551-9. doi:10.1148/radiol.2492072183.
18. Ljumanović R, Langendijk JA, Schenk B, van Watingen M, Knol DL, Leemans CR, et al. Supraglottic carcinoma treated with curative radiation therapy: Identification of prognostic groups with MR imaging. *Radiology*. 2004;232:440-8. doi:10.1148/radiol.2322031001.
19. Forastiere AA, Zhang Q, Weber RS, Maor MH, Goepfert H, Pajak TF, et al. Long-term results of RTOG 91-11: A comparison of three nonsurgical treatment strategies to preserve the larynx in patients with locally advanced larynx cancer. *J Clin Oncol*. 2013;31:845-52. doi:10.1200/JCO.2012.43.6097.
20. Forastiere AA, Ismaila N, Lewin JS, Nathan CA, Adelstein DJ, Eisbruch A, et al. Use of larynx-preservation strategies in the treatment of laryngeal cancer: American Society of Clinical Oncology clinical practice guideline update. *J Clin Oncol*. 2018;36:1143-69. doi:10.1200/JCO.2017.75.7385.
21. Forastiere AA, Goepfert H, Maor M, Pajak TF, Weber R, Morrison W, et al. Concurrent chemotherapy and radiotherapy for organ preservation in advanced laryngeal cancer. *N Engl J Med*. 2003;349:2091-8. doi:10.1056/NEJMoa031317.
22. Paydarfar JA, Birkmeyer NJ. Complications in head and neck surgery: A meta-analysis of postlaryngectomy pharyngocutaneous fistula. *Arch Otolaryngol Head Neck Surg*. 2006;132:67-72. doi:10.1001/archotol.132.1.67.