



Banff classification of renal transplant pathology tutorial

Muhammed Mubarak^{1*}

¹Histopathology Department, Sindh Institute of Urology and Transplantation, Karachi, Pakistan

Correspondence to

Prof. Muhammed Mubarak;
Email:
drmubaraksiut@yahoo.com

Received 17 October 2015
Accepted 29 November 2015
ePublished 19 December 2015

Keywords: Banff classification,
Graft pathology, Renal
pathology, Transplant

Citation: Mubarak M.
Banff classification
of renal transplant
pathology tutorial.
Immunopathol Persa.
2016;2(2):e09.

Key point

Banff classification represents a structured pathological classification system designed to improve the interobserver reproducibility in the reporting and classification of renal allograft pathology. It is categorized into six broad categories. The first category consists of normal findings on all assessment modalities and is discussed and illustrated in this tutorial. It is very important for practicing renal transplant pathologists to familiarize with this pattern in order not to miss important pathological lesions on renal allograft biopsies.

Introduction

Banff classification of renal allograft pathology represents international yardstick for the standardized reporting of renal allograft pathological findings (1-3). In this series, we aim to provide a pictorial view of the classification categories and hints to identify the lesions. This will not only interest the trainees in renal transplant pathology but also practicing renal transplant pathologists.

Banff category 1. Normal

The definition of this category of Banff classification is self-explanatory and requires that all the four components of the kidney graft parenchyma are structurally or morphologically normal. This means that not only the graft parenchyma be free of infiltrate, it should show no acute tubular injury (ATI) or acute tubular necrosis (ATN). It is therefore necessary to examine the entire biopsy material meticulously, at first, at low-power and then at progressively increasing powers for any abnormalities. These can be subtle and may be missed or overlooked, if not examined diligently. Multiple serial sections of the graft biopsy should be examined stained with multiple stains, including hematoxylin and eosin (HE), period acid-Schiff (PAS), trichrome and silver methanamine stains. Among these, a well stained silver stain is of immense help in the interpretation of the fine structural details of the graft tissue as illustrated in Figures 1 to 6 in this tutorial. This is the only category of Banff classification which cannot occur concurrently with any other category (1-3). All other categories of Banff

classification can occur together in variable combinations. Sometimes, three or more causes may be found in one graft biopsy (4). But the normal category is an exclusive diagnosis. The normal appearances of graft biopsy are illustrated in Figures 1 to 6.

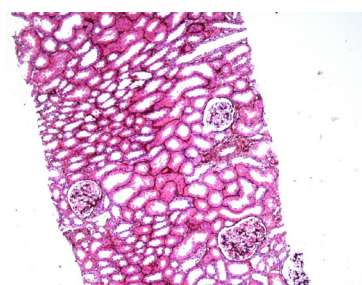


Figure 1. Low-power photograph of one core of renal graft biopsy showing three components of the graft parenchyma. Interstitium is normally not visible under the light microscopy. There is no infiltrate in the biopsy and no significant acute tubular injury (JMS, $\times 50$).

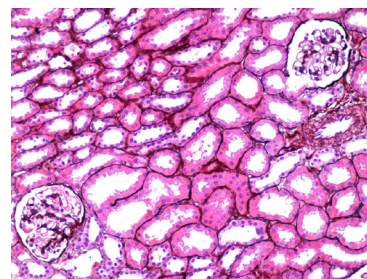


Figure 2. Medium-power photograph of the same renal graft biopsy showing three components of the graft parenchyma in more detail. One small artery can be identified clearly. There is no arteritis. There is no infiltrate in the biopsy and no significant acute tubular injury (JMS, $\times 100$).

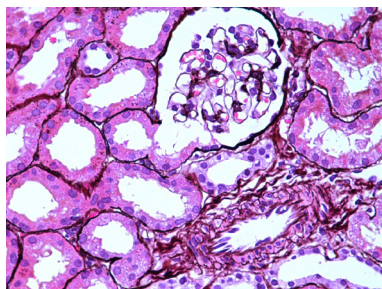


Figure 3. This is further higher magnification of the above biopsy illustrating the three components of the graft parenchyma in more detail. One small artery can be identified clearly. There is no glomerulitis and no arteritis. There is no infiltrate in the biopsy and no significant acute tubular injury (JMS, $\times 200$).

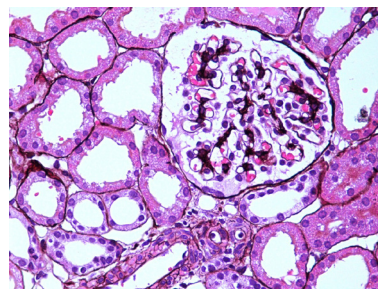


Figure 4. This is high-power photomicrograph of the above biopsy focusing on the glomerular structure. There is no glomerulitis. All capillary lumens are patent. There is no capillary occlusion and no endothelial cell swelling or inflammatory cell infiltration. There is no arteritis in a small artery and no arteriolar hyalinosis or mucinous intimal thickening. No intraluminal thrombosis is seen in either glomerular capillaries or arterioles and small artery. There is no infiltrate in the biopsy and no significant acute tubular injury (JMS, $\times 400$).

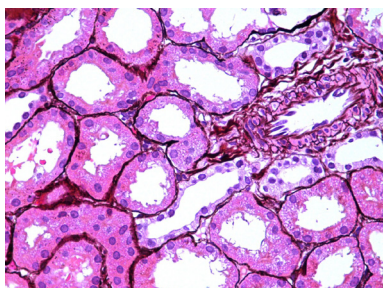


Figure 5. This is high-power photomicrograph of the biopsy focusing on the tubular structure. Majority of tubules in this field are of proximal tubular origin. These are back to back in arrangement with no intervening interstitium being visible. No peritubular capillary dilatation is seen. There is no luminal debris. The lumina are also not patulous or widely dilated, a feature of acute tubular necrosis. There is no significant loss of brush border or cytoplasm of the tubular epithelial cells. Hence, the height of the tubular epithelial cells is maintained. No vacuolization of tubular epithelial cells is seen. This health of the tubular compartment is reflected by no reaction of the interstitial compartment. One small artery with prominent endothelial cells is also present in the field but there is no abnormality in this vessel (JMS, $\times 400$).

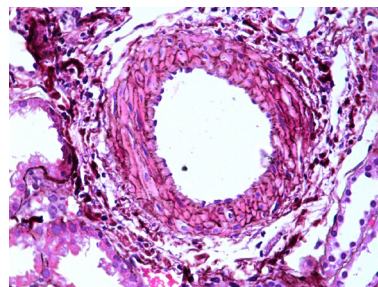


Figure 6. This is high-power photomicrograph of the biopsy focusing on the arterial structure. This is a cross-section of an interlobular size artery surrounded by some fibrous tissue outside adventitia. Minimal lymphocytic infiltrate may be normally present around the vessels. This is considered of no special significance in the Banff classification. There is no intimal arteritis, no transmural arteritis or fibrinoid necrosis. The lumen is also empty and no thrombus or extraneous material is seen (JMS, $\times 400$).

Authors' contribution

MM was the single author of the manuscript.

Conflicts of interest

The author declared no competing interests.

Ethical considerations

Ethical issues (including plagiarism, data fabrication, double publication) have been completely observed by the author.

Funding/Support

None.

References

1. Solez K, Axelsen RA, Benediktsson H, Burdick JF, Cohen AH, Colvin RB, et al. International standardization of criteria for the histologic diagnosis of renal allograft rejection: the Banff working classification of kidney transplant pathology. *Kidney Int.* 1993;44:411-22.
2. Racusen LC, Solez K, Colvin RB, Bonsib SM, Castro MC, Cavallo T, et al. The Banff 97 working classification of renal allograft pathology. *Kidney Int.* 1999;55:713-23.
3. John R, Herzenberg AM. Our approach to a renal transplant biopsy. *J Clin Pathol.* 2010;63:26-37.
4. Kazi JJ, Mubarak M. Pathology of renal transplantation. In: Mubarak M, ed. *Topics in Renal Biopsy and Pathology*. Rijeka: INTECH Open Access Publisher; 2012:159-80.