



A multicentre study of the spectrum of histopathological changes in renal allograft biopsies over a period of nine years from South India

Priyanka Joseph Koshy¹, Anusmitha Tripathy¹, Madhusudan Vijayan¹, Sanjeev Nair¹, Anand Yuvaraj¹, Gopalakrishnan Natarajan², Edwin Fernando³, Georgi Abraham^{1*}

¹Madras Medical Mission, Chennai, India

²Madras Medical College Hospital, Chennai, India

³Stanley Medical College Hospital, Chennai, India

Correspondence to

Georgi Abraham, E-mail: abraham_georgi@yahoo.com,
Email: dr.cmjnazar@live.co.uk

Received 9 June 2016

Accepted 4 Aug. 2016

Published online 14 Sep. 2016

Keywords: Renal transplantation, Allograft biopsies, Graft dysfunction, Banff classification

Citation: Koshy PJ, Tripathy A, Vijayan M, Nair S, Yuvaraj A, Natarajan G, et al. A multicentre study of the spectrum of histopathological changes in renal allograft biopsies over a period of nine years from South India. *Immunopathol Persa.* 2017;3(1):e05.



Abstract

Introduction: Following renal transplant, renal dysfunction is not uncommon. Assessment of histopathological changes in renal dysfunction is done using the Banff '07 Update to the Banff 97 Diagnostic Categories for Renal Allograft Biopsies which is the accepted formulation worldwide.

Objectives: To evaluate the spectrum of histopathological changes seen in renal allograft dysfunction.

Materials and Methods: A retrospective study was conducted in a tertiary care center in South India to analyze all the renal allograft biopsies received by the Department of Pathology, Madras Medical Mission, Chennai, from multiple tertiary centers across India, over a period of 9 years. A total of 1151 renal allograft biopsies from 1120 patients were studied. The biopsies were grouped into six categories according to the Banff 07 update to the Banff 97 diagnostic categories for renal allograft biopsies. Univariate analysis was done and the continuous variables were expressed as percentages.

Results: The study population was predominantly males (75%) with mean age of 37±12.47 years. The median serum creatinine was 2.3 mg/dL. The time of allograft biopsy ranged from 0 hours to 5 years. The maximum number of biopsies obtained for each recipient was three (range 1 to 3). The biopsies were broadly categorized using the Banff criteria (2007 update) into normal (4.95%), antibody-mediated rejection (7.38%), borderline rejection (5.29%), T-cell mediated rejection (31.36%), interstitial fibrosis and tubular atrophy (5.03%) and non-rejection category (41.96%). 46 (3.99%) biopsies were insufficient for categorization.

Conclusion: The appropriate histopathological diagnosis for allograft biopsies aids in tailoring the immunosuppression therapy, prognosticating and appropriate management.

Introduction

Renal transplantation has been the choice of renal replacement therapy in India since 1972. Currently around 6000 renal transplants are performed yearly in India. Though the transplant programme in India is steadily expanding, ensuring optimal graft function is a challenge, owing to scarcity of specialized transplant immunological and pathological services. There is a paucity of large scale multicentre data on renal allograft pathology. Renal allograft outcomes, both short and long-term, depend on tailoring of immunosuppressive agents as per histopathological changes, when allograft dysfunction is evident. Similar to native kidney disease, renal biopsy can

Key point

Allograft biopsy is an invaluable diagnostic tool in detecting the causes for renal allograft dysfunction, for diagnosing both rejection and the non-rejection causes to provide an insight even into the rarer causes of graft dysfunction. The appropriate histopathological diagnosis aids in tailoring the immunosuppression therapy, prognosticating and appropriate management.

aid to the diagnosis of a variety of allograft diseases, which will help in prognosticating the outcomes. Immunosuppressive agents such as calcineurin inhibitors (CNI) and rapamycin can produce toxicity, which

can only be diagnosed by an appropriate interpretation of an allograft biopsy using light microscopy, and immunofluorescence study.

Objectives

This retrospective analysis of allograft biopsies was undertaken to look at the spectrum of histopathological changes seen with renal dysfunction. The objective of this study was to determine the most common causes of renal dysfunction in allograft biopsies from various tertiary care centers in South India.

Materials and Methods

A retrospective study was undertaken in a tertiary care centre in South India to analyze all the renal allograft biopsies received by the department of pathology, Madras Medical Mission, Chennai, from multiple tertiary centers across India. A total of 1151 renal allograft biopsies of 1120 patients presenting with renal allograft dysfunction with a median serum creatinine of 2.3 mg/dL (interquartile range 1.8-3.5 mg/dL) were studied over a period of 9 years between January 2004 to December 2013. Demographic, biochemical and histopathological data were retrospectively collected from the case records. All patients were on maintenance immunosuppressives including various combinations of triple drugs comprising of steroids, azathioprine, CNI, mycophenolate mofetil (MMF) and M-TOR inhibitors when CNI related toxicity was evident.

Two cores of renal allograft tissue were sent to the pathology laboratory, one core in 10% formalin and the other in Michel's fixative. The tissues were processed for light microscopy and immunofluorescence studies. All the paraffin embedded tissues were stained with H&E, PAS, silver and trichrome stains. For immunofluorescence study, the fresh tissues were stained with antibodies – IgG, IgM, IgA, C3, C4d and C1q. Light chains – kappa and lambda was also studied. The biopsies were grouped into six categories according to the Banff 2007 update to the Banff '97 diagnostic categories for renal allograft biopsies (1). Statistical analysis was conducted using EZAnalyze version 3. Univariate analysis was conducted and the continuous variables were expressed as percentages.

Ethical issues

1) The research followed the tenets of the Declaration of Helsinki; 2) Informed consent was obtained for biopsies, and 3) The research was approved by the ethical committee of Madras Medical Mission Hospital, Chennai.

Results

A total of 1151 renal allograft biopsies were included in this retrospective study of 1120 recipients. The study population was predominantly males, constituting 75% (866). The mean age was 37 ± 12.47 years. The median serum creatinine was 2.3 mg/dL (IQR 1.8-3.5 mg/dL). The time of allograft biopsy ranged from 0 hours to 5 years. The maximum number of biopsies obtained for

each recipient was 3 (range 1 to 3). The categorizations of biopsies into Banff 07 update diagnostic categories are shown in Figure 1.

A total of 507 cases were diagnosed with rejection. Majority were T-cell mediated rejection (361, 71%), of which, Type IA cellular rejection was the most common accounting for 176 cases. Further sub-categorization into antibody mediated rejection and T-cell mediated rejection are shown in Figures 2a and 2b.

Of the rest of 644 cases, 57 (8.8%) were reported as normal, 58 biopsies (9.2%) had interstitial fibrosis and tubular atrophy (IFTA), 483 cases (75%) were non rejection causes for post-transplant renal dysfunction and 46 (7%) were insufficient to be reported.

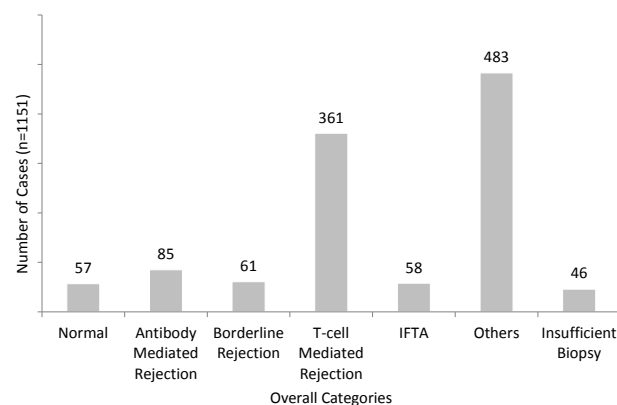


Figure 1. Categorisation of biopsies into Banff 07 Diagnostic categories (n=1151).

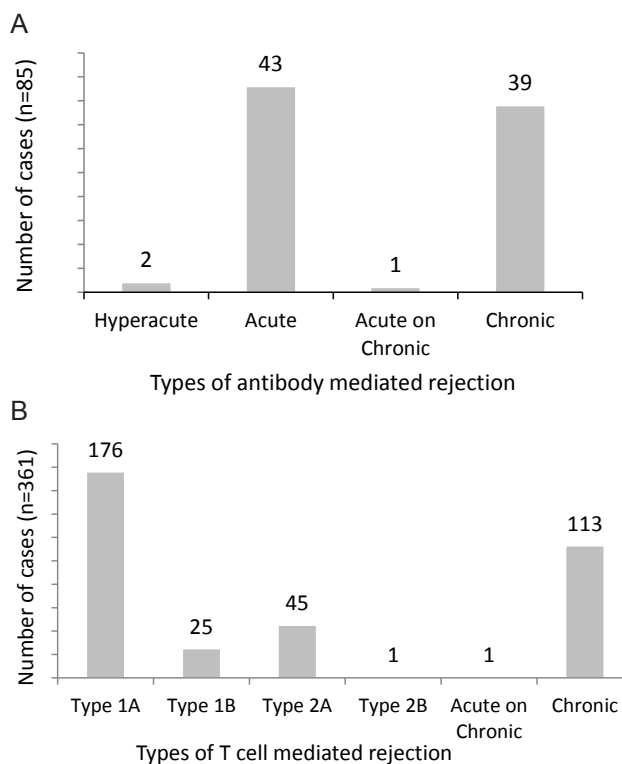


Figure 2. (A) Subcategorisation into antibody mediated rejection (n=85). (B) Subcategorisation into T cell mediated rejection (n=361).

The non-rejection causes of graft dysfunction included acute tubular injury (ATI) which was the most common accounting for 163 cases (33.7%), De Novo/recurrence of primary disease, viral infections (CMV and BK-virus) and CNI toxicity are elaborated in Figures 3 and 4.

We also came across a few unusual histopathological findings in the allograft biopsies, such as eosinophilic rejection.

Discussion

End-stage renal disease (ESRD) resulting from various causes has been rapidly rising worldwide over the past years. The incidence of ESRD in India is 151-232 per million per year (2). Renal transplantation has become the treatment of choice for ESRD, as it provides a relatively better quality of life (2,3). Renal transplant recipients are susceptible to a variety of pathological lesions, not seen in general nephrology practice (4). The allograft biopsy has a pivotal role in the diagnoses of renal dysfunction and aids in its management. As stated by Colvin et al (5), allograft biopsy remains the most definitive and reliable test for graft dysfunction as compared to radionuclide scintigraphy, fine needle aspiration or ultrasound. Multiple studies have shown that adequate interpretation of allograft biopsy can change the clinical management of graft dysfunction and can spare these graft recipients the complications of unnecessary immunosuppression (6-9). However, India is facing the challenge of shortage of skilled nephropathologists and infrastructural facilities for the interpretation of allograft biopsies using all the three domains of light microscopy, immunofluorescence studies and electron microscopy studies. In fact, delayed graft function, if not appropriately diagnosed and managed, the loss of graft will lead to cost escalation and poor recipient outcome. There is a paucity of a large scale multicentre data base on renal allograft pathology in India.

In this study, the spectrum of histopathological changes in allograft biopsies have been categorized according to the Banff 2007 update to the Banff 97 allograft biopsy classification (1).

The major rejection category for graft dysfunction was the T-cell mediated rejection category accounting for 31.3%, wherein, acute T-cell mediated rejection (type IA) was the most common. The reason for this cannot be accurately determined as we could not collect complete data on the induction and dosage of immunosuppression used.

Amongst the non-rejection categories, ATI was most common category, accounting for 33.7%. The second largest category was graft pyelonephritis amounting to 18.8%. In this study, 11.8% were diagnosed with recurrence of primary disease, 13.8% with CNI Toxicity and 2.4% with viral infection (includes BK-virus and CMV). In a similar study from a tertiary care centre in North India conducted by Kandathil et al (10), ATI in 25.2%, CNI toxicity in 16% and infection-related graft biopsies in 10.9% was detected. Our study has many advantages, being one of the largest histopathological studies of allograft biopsies in Southern India. The histopathological diagnosis was based on the latest classification at that time.

Conclusion

Allograft biopsy is an invaluable diagnostic tool in detecting the causes for renal allograft dysfunction, for diagnosing both rejection and the non-rejection causes to provide an insight even into the rarer causes of graft dysfunction. The appropriate histopathological diagnosis aids in tailoring the immunosuppression therapy, prognosticating and appropriate management.

Limitations of the study

This study has the inherent limitations of a retrospective analysis. Since this was purely a pathological study, we

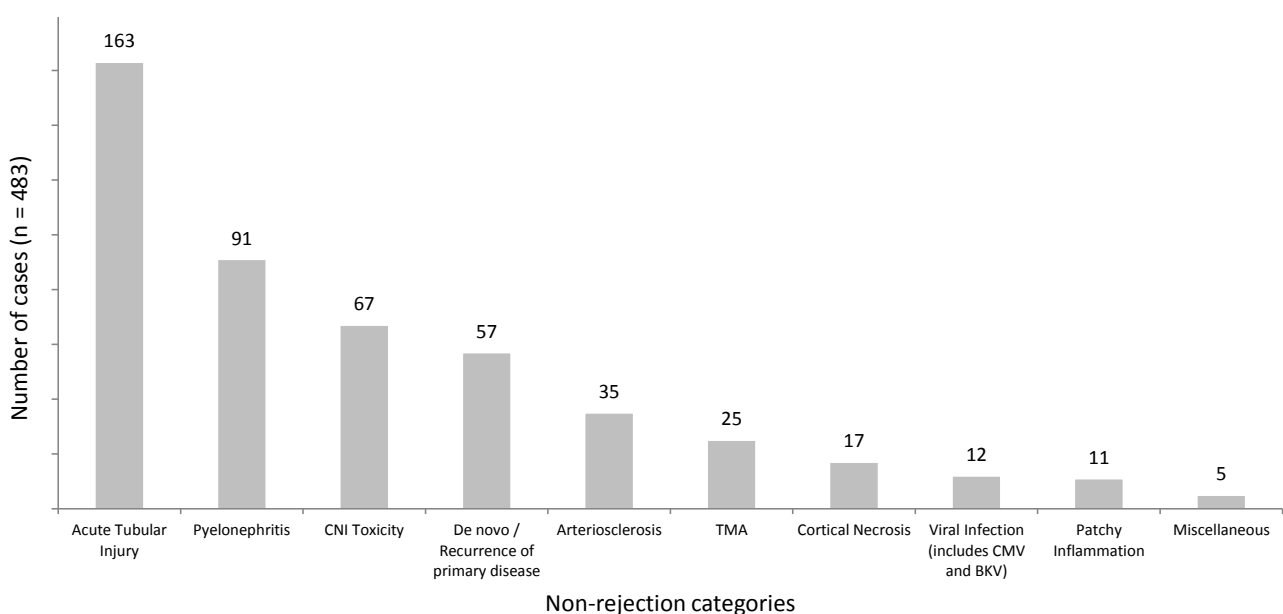


Figure 3. Split up of non rejection causes for posttransplant renal dysfunction (n=483).

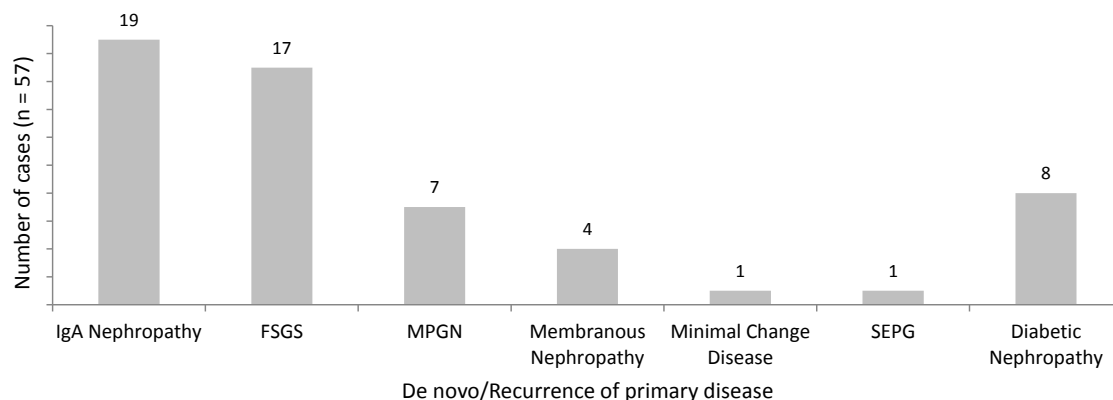


Figure 4. Split up of denovo/recurrence of primary disease (n=57).

lacked all clinical features; however the morphological features helped in the management of transplant recipients.

Authors' contribution

GA and PJK; research proposal initiation and approval, study design, writing of the manuscript. PJK and AT; data collection. MV; statistical analysis. SN, AY, GN, EF and GA; clinical details, renal biopsies, review of scientific content.

Conflicts of interest

The authors declared no competing interests.

Ethical considerations

Ethical issues (including plagiarism, misconduct, data fabrication, falsification, double publication or submission, redundancy) have been completely observed by the authors.

Funding/Support

None.

References

1. Solez K, Colvin RB, Racusen LC, Haas M, Sis B, Mengel M, et al. Banff 07 classification of renal allograft pathology: updates and future directions. *Am J Transplant*. 2008;8:753-760.
2. Veerapan I. Deceased donor kidney transplantation in India. *Health Sci*. 2012;1: JS010.
3. Aryal G, Shah DS. Histopathological evaluation of renal allograft biopsies in Nepal: interpretation and significance. *J of Pathol Nepal*. 2012;2:172-9.
4. Kazi JI, Mubarak M. Pathology of Renal Transplantation, Topics in Renal Biopsy and Pathology. InTech; 2012. Available from: <http://www.intechopen.com/books/topics-in-renal-biopsy-and-pathology/pathology-of-renal-transplantation>
5. Colvin RB. Pathology of renal allografts. In: Colvin RB, Bhan AK, McCluskey RT, eds. *Diagnostic Immunopathology*. New York; Raven Press: 1995. p 329.
6. Colvin RB. The renal allograft biopsy. *Kidney Int*. 1996;50:1069-82.
7. Waltzer WC, Miller F, Arnold A, Anaise D, Rapaport FT. Immunohistologic analysis of human renal allograft dysfunction. *Transplantation*. 1987;42:100-5.
8. Kiss D, Landman J, Mihatsch M, Huser B, Brunner F, Theil G. Risks and benefits of graft biopsy in renal transplantation under cyclosporine-A. *Clin Nephrol* 1992;38:132.
9. Matas AJ, Tellis VA, Sablay L, Quinn T, Soberman R, Veith FJ. The value of needle renal allograft biopsy. III. A prospective study. *Surgery*. 1985;98:922.
10. Kandathil JP, Calton N, Pawar B. Nonrejection pathology of renal allograft biopsies: 10 years experience from a tertiary care center in north India. *Indian J Pathol Microbiol*. 2011;54: 700-5.