



Short-term outcomes following amniotic membrane and conventional dressing in skin graft donor site; a randomized clinical trial

Houshang Soleimani, Jafar Kazemzadeh^{*}

Department of General Surgery, School of Medicine, Urmia University of Medical Sciences, Urmia, Iran

*Correspondence to

Jafar Kazemzadeh, Email: jafarkazemzade48@gmail.com, kazemzadeh.j@umsu.ac.ir

Received 19 October 2021

Accepted 8 May 2022

Published online 31 May 2022

Keywords: Amniotic membrane, Burns, Wound healing, Antimicrobial dressing

Abstract

Introduction: Burn injuries have been associated with a bad prognosis throughout history. Nowadays, the treatment of burn wounds is one of the problems in the country's health care system. There are several treatments for localized burns, such as antimicrobial dressings (using topical antibiotic drugs) and biological dressings (using tissue from living organisms). Biologic dressing with an amniotic membrane is one of the treatments for burned tissues in these patients.

Objectives: This study aimed to investigate the short-term outcomes of dressing with amniotic membrane and routine dressing in graft donor site.

Patients and Methods: This clinical trial study was conducted in the burn ward of Imam Khomeini hospital, Urmia, Iran in 2019. The patients were treated with two amniotic membrane dressings (the patient's left leg) and a local antimicrobial dressing (the patient's right leg). The amniotic membrane was purchased from Sina Cell Company and used to dress the second-degree wound. Patients' right foot was covered with gauze soaked in nitrofurazone dressing since 2 µg of ointment was used for each percent of graft site. The recovery and epithelialization time was assessed one month after the study.

Results: The rate of infection in the two groups did not differ significantly. Furthermore, the rate of wound healing (epithelialization) and post-dressing pain was much better in the group of dressings with amniotic membrane than the group of routine dressings, which was significant ($P < 0.01$) and showed that amniotic membrane dressings are much more effective in healing wounds and reducing pain compared to the routine dressings.

Conclusion: This study showed that the use of amniotic membrane for dressing second-degree burn wounds, compared to the routine dressings, has better results and benefits such as less pain, faster epithelialization, shorter length of stay at hospital and better patient acceptance.

Trial Registration: Registration of trial protocol has been approved by the Iranian Registry of Clinical Trials (identifier: IRCT20181216041996N1, <https://en.irct.ir/trial/35985>, ethical code; IR.UMSU.REC.1397.245).

Citation: Soleimani H, Kazemzadeh J. Short-term outcomes following amniotic membrane and conventional dressing in skin graft donor site; a randomized clinical trial. *Immunopathol Persa*. 2022;8(2):e29314. DOI:10.34172/ipp.2022.29314.

Introduction

Burn is a complication that destroys the skin and subcutaneous tissues in different ways with different intensity and extent. Every year, many people suffer from burns requiring hospitalization, and this causes a lot of medical expenses and the resulting complications can affect patients for several years (1). According to annual estimates, there are 700 000 emergency room visits in the United States due to burn injuries (2, 3).

Burn treatment involves several steps; in the acute stage, the main goal is to rehabilitate patients and prevent side effects (kidney failure, acid and base disorders and infectious complications) and in the next stage, to eliminate their physical, mental and rehabilitation complications (4). There are various methods for topical treatment of second and third degree burns, including

Key point

In a randomized clinical trial study on 33 patients in the burn ward, we found the use of amniotic membrane for dressing second-degree burn wounds had better results and benefits such as less pain, faster epithelialization, shorter length of stay at hospital and better patient acceptance in comparison with routine dressings.

antimicrobial dressings (administration of topical antibiotics) and biological dressings (use of living tissue) (5-7).

Usually after two weeks of hospitalization and necessary local treatments in patients with grade II burns, re-epithelialization occurs and wound secretions are reduced or completely eliminated (8). Current treatments for burn wounds can be divided into three stages; evaluation, treatment, and rehabilitation (9). Wound dressing is

very important and depends on the characteristics of the wound. Grade I wounds with minimal tissue damage do not require dressing. Grade II burns can be treated with daily dressings, topical antibiotics, gauze, and elastic bands. Grade III or deep grade II burns require excision and grafting, and the choice of initial dressing is based on inhibiting bacterial growth and providing a closed dressing until surgery (9,10).

The amniotic membrane was used in 1910 to cover wounds (11). This method was used in 1974 to treat grade III burns and had good results (12). In other studies, the use of amniotic membranes in the treatment of burns reduced pain and prevented severe water and electrolyte disturbances (13). This method also prepares the wound bed for transplantation (14-18). Studies show that the use of biological dressing with amniotic membrane increases tissue epithelialization (16) and also prevents local infection (19).

Objectives

Due to the use of antimicrobial method in Imam Khomeini hospital in Urmia and the high rate of complications due to burns and high mortality and mortality, the present study aimed to compare the short-term consequences of amniotic membrane dressing and routine dressing at graft donor site.

Patients and Methods

Design and settings

This study was a clinical trial carried out on 33 patients in the burn ward of Imam Khomeini hospital, Urmia, Iran

in 2019. The patients underwent amniotic membrane dressing (patient's left foot) and local antimicrobial dressing (patient's right foot) (Figure 1). Patients with underlying diseases (diabetes, kidney failure, hepatitis, immunodeficiency and cardiovascular diseases) and concomitant trauma, as well as patients who died during treatment or did not consent to biological dressing, and those who lost follow-up, were excluded from the study.

Intervention

The amniotic membrane was purchased from "Sina Cell" and used as a second-degree wound dressing at the donor site. The amniotic membrane was prepared sterile from a pair of pregnant women who delivered by cesarean section and had no history of infectious diseases and placed in buckets containing gentamicin and normal saline (80 mg/L). Placental blood samples were sent to the laboratory to check HBsAg, HIV-Ab and HCV Ab tests. After separation from the chorion and purification, the amniotic membrane was placed in normal saline solution containing gentamicin (80 mg/L) and stored at 4°C. Vaseline gas and then wet gas were placed on the amniotic membrane and bandaging was conducted. Evaluations were performed on the first, seventh and fourteenth days after dressing the area and also at discharge. Possible complications and unpredictable changes were accordingly included in these questionnaires. Patients' right foot was gauze impregnated with nitrofurazone and 2 µg of ointment was applied per graft. Local infection was based on clinical criteria and in case of symptoms of infection such as wound discharge,

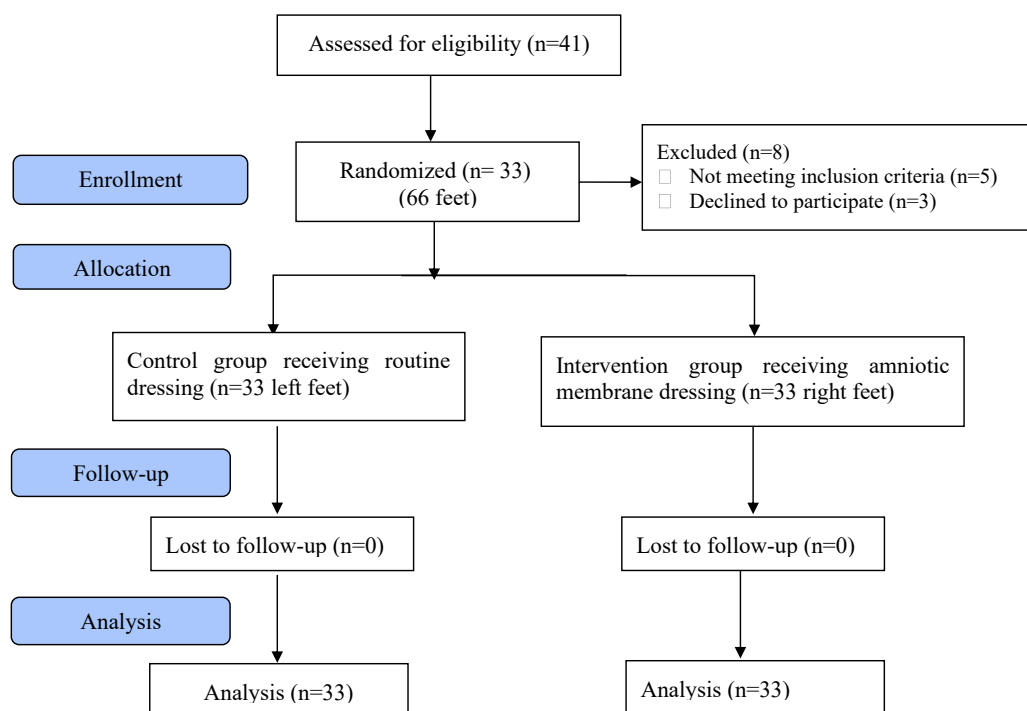


Figure1. CONSORT (consolidated standard of reporting trial) chart for study.

symptoms of cellulite and fever, it was prepared from the culture site.

Data analysis

For descriptive statistics, quantitative variables, central indices and dispersion (mean and standard deviation) were calculated, and for qualitative variables, frequency and percentage were calculated. Chi-square, *t* test, and Fisher's exact test were applied. A *P* value less than of 0.05 was considered significant. All statistical analyses were conducted by SPSS version 18.

Results

A total of 33 patients, 23 (69.8%) males and 10 (30.3%) females with a mean age of 26.82 ± 3.37 years were included in the study (33 right legs with amniotic membrane as intervention group and 33 left legs as control group). On the seventh day in the intervention group, one case (3%) of wound infection (positive culture) was observed. In the control group, wound infection was reported in three patients (9.1%). According to the results of Fisher's exact test, no significant difference between the symptoms of wound infection on the seventh day among groups was detected ($P = 0.30$). On the fourteenth day, no case of infection was reported in routine dressing and amniotic membrane dressing.

Pain severity in patients was reported with visual analogue scale (VAS). In the amniotic membrane group, the mean VAS on the first day was 3.78 ± 1.45 and in the routine dressing group was 4.03 ± 1.53 . This difference between the two groups regarding pain on the first day according to T-test was not significant ($P=0.48$; Table 1). The mean VAS was 1.78 ± 0.97 on the seventh day and in the routine dressing group was 2.70 ± 1.41 , therefore according to the T-test, it was significant ($P=0.04$; Table 2). The severity of pain in the amniotic membrane group was 1.50 ± 0.54 on the fourteenth day and in the routine dressing group was 2.72 ± 1.10 ($P=0.02$; Table 3).

In the right leg, when the amniotic fluid was employed for dressing, the need for analgesia was much less due to less pain. The mean recovery time in the amniotic membrane dressing group was 2.94 ± 1.18 days and in the routine dressing group was 4.14 ± 2.04 days. This difference between the two was significant ($P=0.004$; Table 4). On the seventh day, three patients in the study group (9.1%) and seven patients (21.2%) in the control group had pruritus. This difference was not statistically significant according to Fisher's exact test ($P=0.15$). On the fourteenth day, a significant difference in the frequency of pruritus was observed between the two groups, thereby in the intervention group, one patient (3%) and in the control group, six patients (18.2%) had itching. This difference was statistically significant according to chi-square test ($P=0.04$; Table 5). The frequency of burn wound healing or epithelialization on the seventh day after dressing was 81.8% in the amniotic group and

48.5% in the routine dressing group. According to the statistical test with Fisher's exact test, this difference was statistically significant ($P=0.004$). The frequency of burn wound healing or epithelialization on the fourteenth day after dressing in the amniotic group was 100% and in the routine dressing group was 78.8% ($P=0.005$; Table 6).

Discussion

Burn injury is a complication that is one of the most important incidents in human life related to health due to severe complications and very high mortality. Burn injuries are still one of the leading causes of death and disability in the world (20). Considering the use of antimicrobial method in Imam Khomeini hospital in Urmia and also the high rate of complications due to burns and high mortality and mortality, this clinical trial study aimed to compare the

Table 1. Evaluation of pain score with VAS on the first day in the two groups

VAS score	Mean	Standard deviation	P value
Amniotic group	3.78	1.45	0.48
Routine group	4.03	1.53	

Table 2. Evaluation of pain score with VAS on the seventh day in the two groups

VAS score	Mean	Standard deviation	P value
Amniotic group	1.78	0.97	0.04
Routine group	2.70	1.41	

Table 3. Evaluation of pain score with VAS on the 14th day in the two groups

VAS score	Mean	Standard deviation	P value
Amniotic group	1.50	0.54	0.02
Routine group	2.72	1.10	

Table 4. Comparison of mean recovery time in the two groups

Recovery time (day)	Mean	Standard deviation	P value
Amniotic group	2.94	1.18	0.004
Routine group	4.14	2.04	

Table 5. Frequency of pruritus in amniotic membrane and routine dressing at the graft site

Recovery time (day)	Amniotic group	Routine group	P value
Seventh day	3 (9.1%)	7 (21.2%)	0.15
Fourteenth day	1 (3%)	6 (18.2%)	0.04

Table 6. The rate of burn wound healing and epithelialization in the studied patients on the 7th and 14th days

Healing and epithelialization	No.	%	P value	
Seventh day	Amniotic group	27	81.8	0.004
	Routine group	16	48.5	
Fourteenth day	Amniotic group	33	100	0.005
	Routine group	26	78.8	

short-term consequences of amniotic membrane dressing and routine dressing in graft donor site in 33 patients with mean age of 26.82 ± 3.37 years, of whom 69.7% were male and 30.3% were female.

In our study, there was no significant difference regarding infection between the two methods of using the amniotic membrane and routine dressing. In the study by Branski et al (21), the use of amniotic membrane was not associated with an increased risk of local infection. Several experimental animal studies have confirmed the antimicrobial properties of amniotic membrane in reducing wound infection (21-25). In another study by Bujang et al (24), silver sulfadiazine dressing was used as well but the rate of wound infection was lower in the amniotic dressing group again. Their results were also obtained in our study and no effect of infection was observed in our patients, which could confirm the safety of the amniotic membrane in dressing wounds caused by burns.

In 2015, Ullah et al (25) used the amniotic membrane to dress 370 burn patients. Amniotic membrane creates a dry environment which reduces infection. These results were consistent with the findings of our study. In our study, the mean pain score on the seventh and fourteenth days was significantly different between the two groups, hence patients complained of more pain in the routine dressing. As a result, less pain was reported in the amniotic membrane dressing group, which could be due to the effect of different cytokines in the amniotic membrane, such as transforming growth factor beta, which leads to less analgesic use.

In a study by Mostaque and Rahman (26), the pain status showed a significant difference between the two groups, in which amniotic membrane treatment was more accepted by patients or parents.

Our study showed that the mean recovery time in the amniotic membrane dressing group was 2.94 ± 1.18 days and in contrast in the routine dressing group was 4.14 ± 2.04 days; the difference between the two was significant. In a study by Pakel et al (23), they concluded that the amniotic membrane causes rapid epithelialization of the burn without the risk of metalloprotein accumulation, which was consistent with the results of our study. Accordingly, Subrahmanyam (17) showed that using the amniotic membrane helps premature epithelialization and accelerates wound healing, which was consistent with the results of our study.

Conclusion

Finally, it can be concluded that the employment of amniotic membrane for dressing grade II burn wounds, compared to routine dressing, has good results and benefits including less pain, faster epithelialization, duration, better recovery and reception. Another advantage of amniotic membrane dressing is that in case of burns below 10% that patients do not have the indication for hospitalization,

dressing with amniotic membrane can be conducted on an outpatient admission in the emergency room without the need for anesthesia and operating room.

Limitations of the study

One of the limitations of this study was the need for almost long-term follow-up of the patients and justification and cooperation of as many patients as possible

Authors' contribution

JK and HS designed the study. HS performed the experiments. HS collected data from patients and helped in performance of experiments. JK and HS prepared the primary draft after analysis. Both authors read and signed the final paper.

Conflicts of interest

There are no any conflicts of interest.

Ethical issues

The research followed the principles of the Declaration of Helsinki. Accordingly, written informed consent was taken from all participants before any intervention. This study is a randomized controlled trial which registered in the Iranian Registry of Clinical Trials (IRCT20181216041996N1, <https://en.irct.ir/trial/35985>). The study was reviewed and approved by the committee of Urmia University of Medical Sciences (IR.UMSU.REC. 1397.245) too. This study was extracted from general surgery residency thesis of Houshang Soleimani at this university (Thesis#2582). Besides, ethical issues (including plagiarism, double publication) have been completely considered by the authors.

Funding/Support

This article was taken from the residential thesis of Houshang Soleimani, at the burn surgery department of general surgery at Urmia University of Medical Sciences (Grant #2582).

References

- Gajiwala K, Gajiwala AL. Evaluation of lyophilised, gamma-irradiated amnion as a biological dressing. *Cell Tissue Bank*. 2004;5:73-80. doi: 10.1023/B:CATB.0000034076.16744.4b.
- Association AB. Burn incidence and treatment in the US: 2000 fact sheet. Chicago, IL: ABA. 2007.
- Lee F, Wong P, Hill F, Burgner D, Taylor R. Evidence behind the WHO guidelines: hospital care for children: what is the role of prophylactic antibiotics in the management of burns? *J Trop Pediatr*. 2009;55:73-7. doi: 10.1093/tropej/fmp017.
- Townsend C, Beauchamp R, Evers B, Mattox K. *Textbook of surgery*. Stomach, 19th edn Elsevier, Philadelphia. 2012:1182-226.
- Gallico III GG, O'Connor NE, Compton CC, Kehinde O, Green H. Permanent coverage of large burn wounds with autologous cultured human epithelium. *N Engl J Med*. 1984;311:448-51. doi: 10.1056/NEJM198408163110706.
- Robson MC, Krizek TJ, Koss N, Samburg JL. Amniotic membranes as a temporary wound dressing. *Surg Gynecol Obstet*. 1973;136:904-6.
- Atiyeh BS, Ghanimeh G, Kaddoura IL, Ioannovich J, Al-Amm CA. Split-thickness skin graft donor site dressing: preliminary results of a controlled, clinical comparative study of MEBO and Sofra-Tulle. *Ann Plast Surg*. 2001;46:87-8. doi: 10.1097/00000637-200101000-00023.
- Andersen DK, Billiar TR, Brunicaudi FC, Dunn DL, Hunter JG, Matthews JB, et al. *Schwartz's Principles of Surgery*: McGraw-Hill Education; 2015.

9. Ioannovich J, Magliacani G, Costagliola M, Attiyeh B, Dahm R, Berger A, et al. Moist exposed therapy of partial-thickness burn wounds. A multi-center study. *Eur J Plast Surg.* 2003;26:338-45.
10. Souba WW, Fink MP, Jurkovic GJ. *ACS Surgery: Principles and Practice: B C Decker;* 2007.
11. Bose B. Burn wound dressing with human amniotic membrane. *Ann R Coll Surg Engl.* 1979;61:444-7.
12. Colucho G, Graham WP, Greene AE, Matheson DW, Lynch D. Human amniotic membrane as a physiologic wound dressing. *Arch Surg.* 1974;109:370-3. doi: 10.1001/archsurg.1974.01360030022006.
13. Haberal M, Oner Z, Bayraktar U, Bilgin N. The use of silver nitrate-incorporated amniotic membrane as a temporary dressing. *Burns.* 1987;13:159-63. doi: 10.1016/0305-4179(87)90108-2.
14. Ramakrishnan K, Jayaraman V. Management of partial-thickness burn wounds by amniotic membrane: a cost-effective treatment in developing countries. *Burns.* 1997;23:S33-S6. doi: 10.1016/s0305-4179(97)90099-1.
15. Sawhney C. Amniotic membrane as a biological dressing in the management of burns. *Burns.* 1989;15:339-42. doi: 10.1016/0305-4179(89)90015-6.
16. Sharma SC, Bagree MM, Bhat AL, Banga BB, Singh MP. Amniotic membrane is an effective burn dressing material. *Jpn J Surg.* 1985;15:140-3. doi: 10.1007/BF02469744.
17. Subrahmanyam M. Amniotic membrane as a cover for microskin grafts. *Br J Plast Surg.* 1995;48:477-8. doi: 10.1016/0007-1226(95)90123-x.
18. Waikukul S, Chumniprasas K, Setasubun S, Vajjaradul Y. Application of freeze-dried amniotic membrane: a control trial at the donor site of split-thickness skin grafting. *Bull Hosp Jt Dis Orthop Ins.* 1990;50:27-34.
19. Herndon DN. *Total burn care: Elsevier Health Sciences;* 2007.
20. Charles Bruicardi F, Dana K, Timothy R, Billar Havid L, Dunn Hohn G, Rahaek Em Sxhwarz's pribuciple of surgery. 8th ed MC Graw – Hi: 190:206-209.
21. Branski LK, Herndon DN, Celis MM, Norbury WB, Masters OE, Jeschke MG. Amnion in the treatment of pediatric partial-thickness facial burns. *Burns.* 2008;34:393-9. doi: 10.1016/j.burns.2007.06.007.
22. Kogan S, Sood A, Granick MS. Amniotic Membrane Adjuncts and Clinical Applications in Wound Healing: A Review of the Literature. *Wounds.* 2018;30:168-173.
23. Pakel BA, Bermel MA, Abbott LI, Baumler SK, Nurger MR, Dawson CJ, et al. Split-thickness skin graft donor site care: a quantitative synthesis of the research. *Appl Nurs Res.* 1989; 11:174-82. doi: 10.1016/s0897-1897(98)80296-6.
24. Bujang-Safawi E, Halim A, Khoo T, Dorai A. Dried irradiated human amniotic membrane as a biological dressing for facial burns-A 7-year case series. *Burns.* 2010;36:876-82. doi: 10.1016/j.burns.2009.07.001.
25. Ullah MS, Ferdous K, Mullick MMH, Alam MR, Rahman MS, Khan A. Amnion Membrane Graft Dressing in Superficial Partial Thickness Burn in Pediatric Patients. *Chatt Maa Shi Hosp Med Coll J.* 2015;14:22-5.
26. Mostaque AK, Rahman KB. Comparisons of the effects of biological membrane (amnion) and silver sulfadiazine in the management of burn wounds in children. *J Burn Care Res.* 2011;32:200-9. doi: 10.1097/BCR.0b013e31820aad94.